

## Chronic cerebrospinal venous insufficiency in multiple sclerosis: A sonographer-blinded case-control study

Daniele Imperiale\*, Fabio Melis, Claudia Giaccone, Marilena Guido, Eva Milano, Carlo Buffa, Lucia Appendino

Neurology Unit, Maria Vittoria Hospital, Torino, Italy

### ARTICLE INFO

#### Article history:

Received 12 November 2012

Received in revised form 9 January 2013

Accepted 10 January 2013

Available online 4 February 2013

#### Keywords:

Multiple sclerosis

Jugular veins

Venous insufficiency

Ultrasonography

Doppler

### ABSTRACT

**Objectives:** To evaluate the presence of chronic cerebrospinal venous insufficiency (CCSVI) and cerebral venous anomalies in a consecutive series of patients with multiple sclerosis (MS), other neurologic diseases (NEU) and healthy controls (HC).

**Methods:** A consecutive series of 80 MS patients, 41 HC and 26 NEU cases underwent a transcranial and extracranial echo-color Doppler (ECD) evaluation of cerebrospinal venous return in a sonographer-blinded fashion. According to the original Dr. Zamboni's protocol, CCSVI was diagnosed in presence of  $\geq 2$  ECD venous criteria.

**Results:** We did not observe any association between CCSVI and MS. CCSVI was detected in 17.5% of MS cases, 7.3% of HC and 11.5% of NEU patients ( $p=0.333$ ). The prevalence of internal jugular vein stenosis (IJV) and the proportion of patients with any positive ECD criterion differed significantly among groups, being higher in MS cases versus HC (67.5% and 76.2% versus 48.8% and 41.5%, respectively;  $p=0.005$  and  $p=0.006$ ). No relationship between CCSVI and MS type and severity was evidenced.

**Conclusions:** The present study argues against a positive link between CCSVI and MS risk or severity. Interestingly, a weak association between venous ECD anomalies (in particular IJV stenosis) and MS was observed in our population. This finding should be interpreted with caution due to the possible confounders and needs to be confirmed in large controlled studies.

© 2013 Elsevier B.V. All rights reserved.

## 1. Introduction

Multiple sclerosis (MS) is an immune-mediated demyelinating disease of the central nervous system [1].

A strong association between MS and a new proposed pathologic condition named "chronic cerebrospinal venous insufficiency (CCSVI)" characterized by impaired cerebral venous drainage due to stenosis of cervical veins and assessed by a combined transcranial and extracranial echo-color Doppler (ECD) approach was recently described by the Italian vascular surgeon Dr. Paolo Zamboni [2]. These findings raised enormous interest both among patients and scientists, specially because of the hypothetical treatability of venous anomalies by endovascular procedures [3].

In the last three years, several studies addressed the putative association of MS with CCSVI, and both positive and negative results were published [4–15]. A recent systematic review suggested a

positive link between the two conditions but evidenced also how the marked heterogeneity of published studies did not allow definitive conclusions [16].

The present study was aimed at evaluating the presence of CCSVI and cerebral venous anomalies in a consecutive series of patients with MS, patients with other neurologic disorders different from MS and healthy controls referred to the neurologic department of our general hospital for diagnostic purposes. All the ECD procedures were carried on in a blinded fashion.

## 2. Patients and methods

### 2.1. Study population

From December 2010 to June 2012, we enrolled 80 consecutive patients with clinically defined MS according to McDonald's criteria [17] afferent to our neurologic department (MS group).

In the same period, we also recruited 41 healthy controls without neurologic or other relevant diseases (HC group) and 26 patients with other neurologic diseases different from MS (NEU group) consecutively referred to our neurologic unit for diagnostic purposes (Supplemental Material).

\* Corresponding author at: Neurology Unit, Maria Vittoria Hospital, Via Cibrario 72, 10144 Torino, Italy. Tel.: +39 011 43931; fax: +39 011 4393503; mobile: +39 320 4397441.

E-mail address: [daniele.imperiale@aslto2.piemonte.it](mailto:daniele.imperiale@aslto2.piemonte.it) (D. Imperiale).

Supplementary data associated with this article can be found, in the online version, at <http://dx.doi.org/10.1016/j.clineuro.2013.01.003>.

Exclusion criteria were history of recent stroke or TIA (<1 month), cerebral and/or cervical venous thrombosis, transient global amnesia, vasculitis, cerebral and congenital vascular malformations. MS patients who reported a relapse or received steroids in the previous 30 days were not included in the study.

As well as the general demographic and clinical data, MS type, disease years and EDSS score were recorded in MS patients just prior to the ultrasonographic evaluation [18,19]. In subsequent analysis, relapsing remitting MS patients were classified as “non-progressive MS” whereas secondary progressive (SP) or primary-progressive (PP) ones were classified as “progressive MS”.

## 2.2. Ultrasonography studies

Study participants underwent a non-invasive evaluation of cerebrospinal venous return according to the combined transcranial and extracranial ECD approach of Dr. Zamboni [2]. All the exams were carried on a MyLab-Vinco 25 machine (Esaote Biomedica, Genoa, Italy) with a linear LA332 11.3MHz probe for extracranial measurement and with a phased PA240 2.5Mhz probe for intracranial measurements. The ECD evaluations were performed in a blinded fashion by one of two expert sonographers (F.M. or C.G.), both familiar with extracranial and intracranial venous system investigation. In particular, C.G. attended a specific three-day training course in Dr. Zamboni’s laboratory (University of Ferrara) in September 2010. ECD operators were asked not to interview or examine patients and the study participants were instructed not to reveal their health status. Patients entered the ECD room before the operator and were covered with a blanket (except for head and cervical regions) to avoid direct visual information.

The ECD evaluation included the assessment of internal jugular (IJVs) and vertebral veins (VVs). Flow direction in deep cerebral veins (DCVs) (internal cerebral, Rosenthal and Galeno veins) was achieved by using the classical transtemporal window. All the examinations were performed both in the sitting and supine positions.

Following Dr. Zamboni’s original protocol [2], CCSVI was diagnosed if at least 2 of the following 5 ECD criteria were present.

1. Reflux (>0.88 s) in a single IJV and/or VV in the supine and sitting position, recorded during a short apnoea after normal expiration (not during a Valsalva’s maneuver).
2. Reflux (>0.5 s) in at least one DCV in the supine and sitting position by using the transtemporal window (where necessary, the Quality 3D Doppler profile [QDP] algorithm, provided in MyLab-Vinco 25 instrumentation, was employed to sensitize flow detection in DCVs) [20].
3. High-resolution B-mode evidence of IJV stenosis, defined as a reduction of the cross-sectional area (CSA)  $\leq 0.3$  cm<sup>2</sup> measured in a transversal plane in the supine position (this criterion was considered positive also in the presence of IJV septa or valve malformations) [21].
4. Lack of Doppler-detectable flow in IJVs and/or VVs despite deep inspirations both in the supine and sitting positions.
5. Lack of IJV diameter decrease in the sitting position, indicative of reverted postural control of the main cerebral venous drainage pathways.

The inter-rater agreement of our two ECD operators and the quality of blinding were preliminarily assessed on 16 individuals (12 MS, and 4 HC) recruited independently from the study groups. Diagnosis of CCSVI status was concordant in 87.5% of subjects (Cohen’s kappa coefficient = 0.6) [22]. The effectiveness of blinding

procedures resulted to be satisfactory: in fact, there was no significant association between the subjects’ actual status (MS or HC) and what hypothesized by each sonographer prior the ECD examination ( $p = 0.315$  for F.M.;  $p = 0.302$  for C.G.).

## 2.3. Sample size

Sample size was estimated starting from the values of CCSVI prevalence in MS patients and HC (55.7% and 11.4%, respectively) reported in a recent systematic review [16]. Considering a two-tailed alpha error of 0.01 and a power of 80%, the minimum number of individuals sufficient to detect CCSVI in 45% of MS cases and in 10% of controls was of 38 subjects per group.

## 2.4. Statistical analysis

The open-source software package R was used for all statistical analysis [23].

The Kolmogorov–Smirnov test was preliminarily employed to check the distribution of continuous variables for deviation from normal. Parametric data were expressed as mean and standard deviation (SD) and compared by one-way ANOVA. Nonparametric data were expressed as median and interquartile range (IQR) and compared by the Kruskal–Wallis test. Categorical variables were expressed as proportions and compared by the Fisher’s exact test and the chi-square test for trend. Sensitivity, specificity, positive likelihood ratio (LR) and crude odds ratio (OR) values with 99% confidence interval (99% CI) between MS cases and HC were obtained by direct computation from contingency tables. Where necessary, pooled median values were employed to dichotomize continuous variables.

Bonferroni’s correction was applied to avoid false associations due to the multiple group design and the significance limit was assumed at  $p < 0.01$  in two-tailed tests.

## 2.5. Ethical statement

The present study has been approved by the “Comitato Etico - Azienda Sanitaria Locale Torino 2” (Protocol No.73/12/10). Written informed consent was obtained by all participants.

## 3. Results

General characteristics of study groups are reported in Table 1. No difference in age and sex composition was evident across the study groups.

Clinical data of MS cases are summarized in Table 2. Age, EDSS score and disease duration were significantly lower in patients with RRMS.

Table 3 details the ECD findings in study groups. No association between CCSVI and MS was observed. CCSVI was diagnosed in 17.5% of MS cases, 7.3% of HC and 11.5% of NEU patients ( $p = 0.333$ ). As regards single ECD criteria, reflux in IJVs and/or VVs (1st criterion) or in DCVs (2nd criterion) was detected only in a few patients with no significant difference among groups. Also the 4th and the 5th ECD criteria (i.e. the absence of flow in IJVs and/or VVs and the reverted postural control of venous drainage) were evenly distributed in the study groups. On the other hand, prevalence of IJV stenosis (3rd criterion) differed significantly among groups ( $p = 0.005$ ). In particular, a proximal IJV stenosis was detected in 67.5% of MS cases compared to 41.5% of HC ( $p = 0.007$ ). The proportion of patients with presence of any positive criterion was not equally distributed across groups ( $p < 0.0001$ ), being significantly higher in MS cases than in HC (23.8% versus 51.2%;  $p = 0.005$ ).

Considering only the MS and HC groups, a significant trend toward a higher number of positive criteria in MS cases compared

**Table 1**  
General characteristics of study groups.

	MS group (n=80)	HC group (n=41)	NEU group (n=26)	p*
Age (years) <sup>a</sup> , mean ± SD	45.5 ± 10.0	44.9 ± 10.5	44.0 ± 11.9	0.812
Males, n (%)	29 (36.3)	18 (43.9)	15 (57.7)	0.048
Disease years <sup>b</sup> , median (IQR)	10 (13.75)	/	/	/
EDSS score <sup>c</sup> , median (IQR)	2.5 (2.5)	/	/	/
No therapy, n (%)	30 (37.5)	/	/	/

<sup>a</sup> Defined as age at ultrasonographic evaluation.

<sup>b</sup> Defined as the difference between age at ultrasonographic evaluation and age at disease onset.

<sup>c</sup> Assessed just prior the ultrasonographic evaluation.

\* The p value is referred to the comparison among all groups.

**Table 2**  
Clinical features of MS patients.

	RRMS (n=56)	SPMS (n=20)	PPMS (n=4)	p*
Age (years) <sup>a</sup> , mean ± SD	42.2 ± 8.9	52.7 ± 8.9	54.7 ± 5.6	<0.0001
Males, n (%)	23 (41.1)	5 (25.0)	1 (25.0)	0.455
Disease years <sup>b</sup> , median (IQR)	7 (9.8)	20 (13)	11.5 (17.5)	<0.0001
EDSS score <sup>c</sup> , median (IQR)	1.8 (2)	5.3 (3.4)	6.0 (4.0)	<0.0001
No therapy, n (%)	19 (33.9)	10 (50)	1 (25)	0.067

<sup>a</sup> Defined as age at ultrasonographic evaluation.

<sup>b</sup> Defined as the difference between age at ultrasonographic evaluation and age at disease onset.

<sup>c</sup> Assessed just prior the ultrasonographic evaluation.

\* The p value is referred to the comparison among all groups.

**Table 3**  
CCSVI and single ECD criteria in study groups.

	MS group (n=80)	HC group (n=41)	NEU group (n=26)	p*
CCSVI diagnosis, n (%)	14 (17.5)	3 (7.3)	3 (11.5)	0.333
1st ECD criterion (Reflux in the IJVs and/or VVs)	3 (3.8)	1 (2.4)	0 (0)	1.00
2nd ECD criterion (Reflux in the DCVs)	0 (0)	1 (2.4)	0 (0)	0.44
3rd ECD criterion (Evidence of IJV stenosis)	54 (67.5)	17 (41.5)	9 (34.6)	0.005
4th ECD criterion (Absence of flow in the IJVs and/or VVs)	14 (17.5)	3 (7.3)	6 (23.1)	0.086
5th ECD criterion (Reverted postural control)	7 (8.8)	2 (4.9)	2 (7.7)	0.755
Any positive ECD criterion, n (%)	61 (76.2)	20 (48.8)	12 (46.2)	<0.0001

\* The p value is referred to the comparison among all groups.

**Table 4**  
Venous ECD findings in MS versus HC group. Sensitivity, specificity, positive LR and OR with 99%CI.

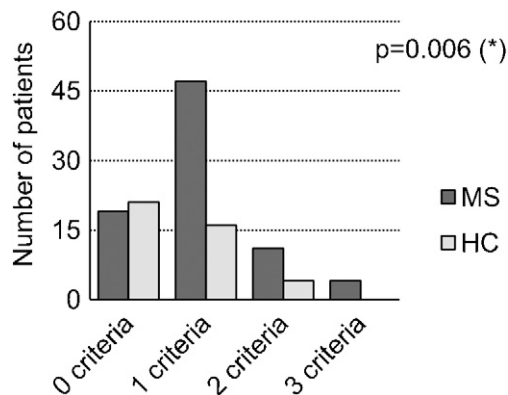
	Sensitivity, % (99% CI)	Specificity, % (99% CI)	Positive LR (99% CI)	OR (99% CI)	p
CCSVI diagnosis	82.4 (52.2–100)	36.5 (25.1–49)	1.3 (0.9–1.8)	2.7 (0.5–13.6)	0.170
1st ECD criterion	75.0 (18.4–100)	34.2 (23.6–45.9)	1.1 (0.5–2.4)	1.6 (0.1–20.1)	1.0
2nd ECD criterion	0 (0–96.4)	33.3 (22.9–44.8)	0	/	0.338
3rd ECD criterion	76.1 (61.7–87.6)	48.0 (30.6–65.7)	1.5 (1–2.2)	2.9 (1.1–8.1)	0.006
4th ECD criterion	82.4 (52.2–100)	36.5 (25.1–49)	1.3 (0.9–1.8)	2.7 (0.5–13.6)	0.170
5th ECD criterion	77.8 (36.3–100)	34.8 (23.9–46.8)	1.2 (0.7–2.0)	1.9 (0.3–13.1)	0.501
Any positive criterion	75.3 (61.9–86.4)	52.5 (32.9–71.7)	1.6 (1–2.5)	3.4 (1.2–9.5)	0.005

to HC was observed ( $p=0.006$ ) (Fig. 1). Furthermore, MS status resulted to be weakly associated to the detection of a proximal IJV stenosis (OR 2.9, 99%CI 1.1–8.1;  $p=0.006$ ) or the presence of any positive ECD criterion (OR 3.4; 99%CI 1.2–9.5;  $p=0.005$ ). However, the corresponding values of sensitivity, specificity and positive LR were low (Table 4).

To explore the possible relationship between MS type and severity and CCSVI status, MS patients were subsequently classified as CCSVI-positive and CCSVI-negative. No difference in age, gender, MS type (progressive versus non-progressive), disease years and EDSS scores was observed between CCSVI-positive and CCSVI-negative MS cases (Table 5).

#### 4. Discussion

This case-control study was aimed at evaluating the presence of venous anomalies and CCSVI (defined according to Dr. Zamboni's criteria) in a consecutive series of MS subjects, healthy individuals



**Fig. 1.** Number of positive ECD criteria in MS and HC groups. (\*) Chi-square test for trend.

**Table 5**  
General and clinical characteristics of CCSVI-positive versus CCSVI-negative MS patients.

	CCSVI-positive (n = 14)	CCSVI-negative (n = 66)	p
Age (years) <sup>a</sup> , mean ± SD	43.3 ± 9.2	45.9 ± 10.2	0.374
Males, n (%)	5 (35.7)	24 (36.3)	1
Disease years <sup>b</sup> , median (IQR)	12.5 (13)	9.5 (14.5)	0.771
EDSS score <sup>c</sup> , median (IQR)	2 (4.5)	2.8 (2.6)	0.638
"Progressive MS", n (%)	4 (28.6)	16 (24.2)	1
No therapy, n (%)	5 (35.7)	15 (22.7)	0.499

<sup>a</sup> Defined as age at ultrasonographic evaluation.

<sup>b</sup> Defined as the difference between age at ultrasonographic evaluation and age at disease onset.

<sup>c</sup> Assessed just prior the ultrasonographic evaluation.

and patients with other neurologic diseases. Due to its multiple group design, we assumed a stringent level of significance ( $p < 0.01$ ) to avoid spurious associations. Two expert sonographers, whose agreement in CCSVI detection resulted to be "good" in a preliminary pilot study, performed all the ECD procedures in a blinded fashion.

No relationship between CCSVI and MS was observed in the present study, being CCSVI prevalence not significantly different across groups. The lack of association of MS with CCSVI in our population is in agreement with the results of some studies in which the prevalence of CCSVI was not significantly different in MS patients versus non-MS controls [4,8,10–13,15]. Instead, other studies supported the relationship between MS and CCSVI [6,7,9,14], but the strength of that association was decisively lower compared to Dr. Zamboni's original findings [2]. Various factors may be advocated to explain these contradictory results. All published studies are heterogeneous in sample sizes, blinding procedures, characteristics of control groups, type of ECD instrumentation [16]. Similarly to other ultrasound diagnostic techniques, ECD evaluations of cervical veins may be affected by operators' (general expertise, specific training, etc.) and patients' components (blood circulating volume, head position, anatomic variants, etc.) [5]. Furthermore, the reliability of CCSVI criteria itself is debated. The European Society of Neurosonology and Cerebral Hemodynamics has recently expressed serious concerns about their accuracy [24]. Indeed, as well as having methodological problems and being susceptible to external confounders, the original CCSVI criteria are based on ECD findings obtained in settings different from the study of cerebral venous routes [25–28]. Notably, the CCSVI prevalence values in our MS cases and HC were strikingly similar to what found in a very recent population-based study from Sicily (Italy) in which the ECD exams were also performed in a blinded fashion and the study subjects were randomly selected from an incident cohort of MS patients and from the general practitioners' cabinet lists to avoid selection bias [14].

We observed a significant trend toward a higher number of positive criteria in MS patients compared to HC. Besides, the presence of any positive ECD criterion was associated to MS status in our population but the corresponding values of sensitivity, specificity, positive likelihood ratio were low and had large confidence intervals. Considering each CCSVI criterion separately, we never found DCV reflux (2nd criterion) in MS patients even if we employed a specifically designed software (QDP). Interestingly, the prevalence of IJV stenosis (3rd criterion) resulted to significantly higher in MS cases than in HC and NEU subjects.

A very low prevalence of DCV reflux (2nd criterion) both in MS and non-MS subjects was reported also in other studies. [4,5,7,8,10,13]. The ultrasonographic evaluation of DCVs is certainly challenging. In fact, according to the frequent variations of cerebral venous anatomy in general population, also the blood flow

direction in cortical veins draining in DCVs may be extremely variable [29]. In this view, the International Society for Neurovascular Disease consensus panel (which includes also Dr. Zamboni) has recently stated that the assessment of the DCVs needs further evaluation and must be excluded from any CCSVI screening protocol [30].

The higher frequency of IJV stenosis in our MS cases compared to HC has been also reported by other authors, but prevalence values were greatly different across studies. Patti et al. diagnosed a proximal IJV stenosis in 22.3% of MS cases, 10% of HC and 7.3% of neurologic controls [14]. Baracchini et al. reported a proximal IJV stenosis in 16% of MS cases, 0% of HC and 1.7% of neurologic patients [7]. Zivadonov et al. found a significant difference in prevalence of IJV stenosis in MS patients versus neurologic and non-neurologic controls (respectively 63.5%, 46.2% and 38.7%) [9]. Kantarci et al. reported that the evidence of IJV stenosis was the only extracerebral CCSVI criterion that distinguished MS cases from HC [31]. Intriguingly, a recent pathologic study evidenced a frequent occurrence of intraluminal IJVs abnormalities in MS patients, possibly explaining the raised prevalence of IJV stenosis [32]. Moreover, Chambers et al. observed a raised prevalence of IJV stenosis in MS cases compared to controls, as well as an apparent increase in IJV variation in early and mild MS cases [15]. The association of MS with IJV stenosis should be interpreted with caution since the possible confounders. Indeed, the wall of IJV is thin and may be easily compressed by the ultrasound probe and/or the surrounding anatomic structures. The IJV caliber physiologically varies along its course, being dilated at superior and inferior bulbs and narrowed in its middle tract, and it may be influenced by the patient's position and hydration state, breathing phases, intrathoracic and central venous pressures [33,34]. Finally, anatomical variants of cervical venous routes are common in the general population [29]. Actually, all these factors pertain to both MS patients and HC and therefore did not explain the observation of a raised prevalence of IJV stenosis in MS cases versus non MS controls reported also by other research groups [7,9,14,15,31]. In the view of the vascular theory of MS, the presence of a IJV stenosis could represent an obstacle to venous drainage pathways, leading to increased pressure in the cerebral venous system, raised blood–brain barrier permeability, perivenous iron deposition and subsequent inflammatory changes.

No association between CCSVI status and MS features (type of disease, duration, severity) was observed in our study. In particular, CCSVI-positive and CCSVI-negative MS patients did not differ in disease years, clinical course ("progressive MS" versus "non-progressive MS") and EDSS score. Similar findings were also reported by some authors [11,35] but not by others, who described a positive link between CCSVI and MS disability or progressive course [9,14,36]. Beyond the heterogeneity of study populations, this discrepancy could be also related to the effectiveness of blinding procedures. Indeed, it is presumably difficult to keep the blinding status during the ECD evaluation of a "progressive MS" patient (SPMS or PPMS) with a severe clinical picture and a high EDSS score.

## 5. Conclusions

The present study argues against the positive relationship between CCSVI and MS risk and severity reported by other groups. The weak association between venous ECD anomalies (in particular IJV stenosis) and MS risk observed in our population is certainly interesting but should be interpreted with caution due to the possible confounders. In this view, large controlled studies are mandatory to elucidate any role of cerebrospinal venous anomalies in MS pathogenesis.

## Acknowledgements

The authors acknowledge Mrs Marina Pagliano for the valuable assistance in employing blinding procedures.

## References

- [1] Bar-Or A. The immunology of multiple sclerosis. *Seminars in Neurology* 2008;28:29–45.
- [2] Zamboni P, Galeotti R, Menegatti E, Malagoni AM, Tacconi G, Dall'Ara S, et al. Chronic cerebrospinal venous insufficiency in patients with multiple sclerosis. *Journal of Neurology, Neurosurgery and Psychiatry* 2009;80:392–9.
- [3] Rudick RA. Multiple sclerosis: is multiple sclerosis caused by venous insufficiency? *Nature Reviews Neurology* 2010;6:472–4.
- [4] Krogias C, Schröder A, Wiendl H, Hohlfeld R, Gold R. “Chronic cerebrospinal venous insufficiency” and multiple sclerosis: critical analysis and first observation in an unselected cohort of MS patients. *Nervenarzt* 2010;81:740–6.
- [5] Doepp F, Paul F, Valdueza JM, Schmierer K, Schreiber SJ. No cerebrocervical venous congestion in patients with multiple sclerosis. *Annals of Neurology* 2010;68:173–83.
- [6] Al-Omari MH, Rousan LA. Internal jugular vein morphology and hemodynamics in patients with multiple sclerosis. *International Angiology* 2010;29:115–20.
- [7] Baracchini C, Perini P, Calabrese M, Causin F, Rinaldi F, Gallo P. No evidence of chronic cerebrospinal venous insufficiency at multiple sclerosis onset. *Annals of Neurology* 2011;69:90–9.
- [8] Mayer CA, Pfeilschifter W, Lorenz MW, Nedelmann M, Bechmann I, Steinmetz H, et al. The perfect crime? CCSVI not leaving a trace in MS. *Journal of Neurology, Neurosurgery and Psychiatry* 2011;82:436–40.
- [9] Zivadinov R, Marr K, Cutter G, Ramanathan M, Benedict RH, Bergsland N, et al. Prevalence, sensitivity, and specificity of chronic cerebrospinal venous insufficiency in MS. *Neurology* 2011;77:138–44.
- [10] Sundstrom P, Wahlin A, Ambarki K, Birgander R, Eklund A, Malm J. Venous and cerebrospinal fluid flow in multiple sclerosis: a case-control study. *Annals of Neurology* 2010;68:255–9.
- [11] Centonze D, Floris R, Stefanini M, Rossi S, Fabiano S, Castelli M, et al. Proposed chronic cerebrospinal venous insufficiency criteria do not predict multiple sclerosis risk or severity. *Annals of Neurology* 2011;70:51–8.
- [12] Floris R, Centonze D, Fabiano S, Stefanini M, Marziali S, Del Giudice C, et al. Prevalence study of chronic cerebrospinal venous insufficiency in patients with multiple sclerosis: preliminary data. *Radiologia Medica* 2012;117:855–64.
- [13] Blinkenberg M, Akeson P, Sillesen H, Lövgård S, Sellebjerg F, Paulson OB, et al. Chronic cerebrospinal venous insufficiency and venous stenoses in multiple sclerosis. *Acta Neurologica Scandinavica* 2012, <http://dx.doi.org/10.1111/j.1600-0404.2012.01671.x>.
- [14] Patti F, Nicoletti A, Leone C, Messina S, D'Amico E, Lo Fermo S, et al. Multiple sclerosis and CCSVI: a population-based case control study. *PLoS ONE* 2012;7:e41227, <http://dx.doi.org/10.1371/journal.pone.0041227>.
- [15] Chambers B, Chambers J, Cameron H, Macdonnell R. Chronic cerebrospinal venous insufficiency is not more prevalent in patients with mild multiple sclerosis: a sonographer-blinded, case-control ultrasound study. *Multiple Sclerosis* 2012. Sep 7 [Epub ahead of print].
- [16] Laupacis A, Lillie E, Dueck A, Straus S, Perrier L, Burton JM, et al. Association between chronic cerebrospinal venous insufficiency and multiple sclerosis: a meta-analysis. *CMA* 2011;183:1203–12.
- [17] Polman CH, Reingold SC, Edan G, Filippi M, Hartung HP, Kappos L, et al. Diagnostic criteria for multiple sclerosis: 2005 revisions to the “McDonald Criteria”. *Annals of Neurology* 2005;58:840–6.
- [18] Lublin FD, Reingold SC. Defining the clinical course of multiple sclerosis: results of an international survey: National Multiple Sclerosis Society (USA) Advisory Committee on Clinical Trials of New Agents in Multiple Sclerosis. *Neurology* 1996;46:907–11.
- [19] Kurtzke JF. Rating neurologic impairment in multiple sclerosis: an expanded disability status scale (EDSS). *Neurology* 1983;33:1444–52.
- [20] Zamboni P, Menegatti E, Bartolomei I, Galeotti R, Malagoni AM, Tacconi G, et al. Intracranial venous haemodynamics in multiple sclerosis. *Current Neurovascular Research* 2007;4:252–8.
- [21] Zamboni P, Galeotti R, Menegatti E, Malagoni AM, Giancesini S, Bartolomei I, et al. A prospective open-label study of endovascular treatment of chronic cerebrospinal venous insufficiency. *Journal of Vascular Surgery* 2009;50:1348–58.
- [22] Landis JR, Koch GG. The measurement of observer agreement for categorical data. *Biometrics* 1977;33:159–74.
- [23] R Development Core Team. R: a language and environment for statistical computing. Vienna, Austria: R Foundation for Statistical Computing; 2012 <http://www.R-project.org>
- [24] Baracchini C, Valdueza JM, Del Sette M, Baltgaile G, Bartels E, Bornstein NM, et al. CCSVI and MS: a statement from the European Society of neurosonology and cerebral hemodynamics. *Journal of Neurology* 2012. May 31 [Epub ahead of print].
- [25] Nedelmann M, Eicke BM, Dieterich M. Functional and morphological criteria of internal jugular valve insufficiency as assessed by ultrasound. *Journal of Neuroimaging* 2005;15:70–5.
- [26] Hoffmann O, Weih M, von Muster T, Schreiber S, Einhäupl KM, Valdueza JM. Blood flow velocities in the vertebral veins of healthy subjects: a duplex sonographic study. *Journal of Neuroimaging* 1999;9:198–201.
- [27] van Bemmelen PS, Bedford G, Beach K, Strandness DE. Quantitative segmental evaluation of venous valvular reflux with duplex ultrasound scanning. *Journal of Vascular Surgery* 1989;10:425–31.
- [28] Sarin S, Somerville K, Farrah J, Scurr JH, Coleridge Smith PD. Duplex ultrasonography for assessment of venous valvular function of the lower limb. *British Journal of Surgery* 1994;81:1591–5.
- [29] Werner DJ, Siskin GP, Mandato K, Englander M, Herr A. Review of venous anatomy for venographic interpretation in chronic cerebrospinal venous insufficiency. *Journal of Vascular and Interventional Radiology* 2011;22:1681–90.
- [30] Nicolaides AN, Morovic S, Menegatti E, Viselner G, Zamboni P. Screening for chronic cerebrospinal venous insufficiency (CCSVI) using ultrasound: recommendations for a protocol. *Functional Neurology* 2011;26:229–48.
- [31] Kantarci F, Albayram S, Demirci NO, Esenkaya A, Uluduz D. Chronic cerebrospinal venous insufficiency: does ultrasound really distinguish multiple sclerosis subjects from healthy controls? *European Radiology* 2011;22:970–9.
- [32] Diaconu CI, Staugaitis SM, Fox RJ, Rae-Grant A, Schwanger C, McBride JM. A technical approach to dissecting and assessing cadaveric veins pertinent to chronic cerebrospinal venous insufficiency in multiple sclerosis. *Neurological Research* 2012;34:810–8.
- [33] Valdueza JM, von Munster T, Hoffmann O, Schreiber S, Einhäupl KM. Postural dependency of the cerebral venous outflow. *Lancet* 2000;355:200–1.
- [34] Schreiber S, Lurtzing F, Gotze R, Doepp F, Klingebiel R, Valdueza JM. Extrajugular pathways of human cerebral venous blood drainage assessed by duplex ultrasound. *Journal of Applied Physiology* 2003;94:1802–5.
- [35] Baracchini C, Perini P, Causin F, Calabrese M, Rinaldi F, Gallo P. Progressive multiple sclerosis is not associated with chronic cerebrospinal venous insufficiency. *Neurology* 2011;77:844–50.
- [36] Bastianello S, Romani A, Viselner G, Tibaldi EC, Giugni E. Chronic cerebrospinal venous insufficiency in multiple sclerosis: clinical correlates from a multicentre study. *BMC Neurology* 2011;11:132.